

# A High Ratio of Insulin-like Growth Factor II/Insulin-like Growth Factor Binding Protein 2 Messenger RNA as a Marker for Anaplasia in Meningiomas<sup>1</sup>

Ann-Christin Sandberg Nordqvist,<sup>2</sup> Myriam Peyrard, Helena Pettersson, Tiit Mathiesen, V. Peter Collins, Jan P. Dumanski, and Martin Schalling

Department of Molecular Medicine, Neurogenetics Unit [A.-C. S. N., M. S.], Clinical Genetics Unit [M. P., J. P. D.], Ludwig Institute for Cancer Research, Stockholm Branch, Clinical Unit and Department of Oncology-Pathology [H. P., V. P. C.], and Department of Neurosurgery [T. M.], Karolinska Hospital, Building L8:00, S-171 76 Stockholm, Sweden

## Abstract

Insulin-like growth factors (IGFs) I and II have been implicated as autocrine or paracrine growth promoters. These growth factors bind to specific receptors, and the response is modulated by interaction with IGF-binding proteins (IGFBPs). We observed a strong correlation between anaplastic/atypical histopathology and a high IGF-II/IGFBP-2 mRNA ratio in a set of 68 sporadic meningiomas. A strong correlation was also found between clinical outcome and IGF-II/IGFBP-2 ratio, whereas previously used histochemical markers were less correlated to outcome. We suggest that a high IGF-II/IGFBP-2 mRNA ratio may be a sign of biologically aggressive behavior in meningiomas that can influence treatment strategies. We propose that low IGFBP-2 levels in combination with increased levels of IGF-II would result in more free IGF-II and consequently greater stimulation of proliferation.

## Introduction

Meningiomas represent 15–20% of primary intracranial tumors (1). Five to 10% of meningiomas are malignant with anaplastic histology, high recurrence rate, and invasive/metastatic potential (2). IGF<sup>3</sup>-II is involved in human normal fetal growth and development, where it stimulates cell proliferation (3). IGF-II and IGF receptors have been detected in a number of human tumors, suggesting that IGF-II acts as an autocrine or paracrine growth factor (4). The carcinogenic effect of IGF-II has been examined in transgenic mice, where increased circulating levels of IGF-II resulted in the development of diverse types of tumors (5). In breast cancer-derived lines, overexpression of IGF-II induced phenotypic changes associated with malignant progression, which could be inhibited by blocking the type I IGF receptor (6). Relaxation of IGF-II imprinting has been reported in a number of human cancers, including rhabdomyosarcoma, lung cancer, and Wilms' tumor, reviewed by Werner and Le Roith (4). In the central nervous system, IGF-II is mainly expressed in the choroid plexus and in the leptomeninges (7), tissues that also express the biologically active type I IGF receptor (8). IGFBPs modify the type I IGF receptor-mediated activity, thereby regulating the activity of IGFs. IGFBP-2 is mainly synthesized in the same regions as IGF-II, the choroid plexus and leptomeninges (7). The colocalization of IGF-II and IGFBP-2 mRNA and peptide suggest that IGFBP-2 may modulate the biological actions of IGF-II on target cells, predominantly by exerting an inhibitory influence (9). This inhibition may thus be of relevance to

the ability of IGF-II to exert its auto- or paracrine effects on target cells. It is consequently possible that low IGFBP-2 levels in combination with increased levels of IGF-II would result in more free IGF-II and consequently greater stimulation of proliferation. Some studies have presented evidence for the presence of IGF-II in CNS tumors. Thus, high IGF-II mRNA levels have been found in meningiomas (10–12), whereas both high (12, 13) and nondetectable (10, 11) levels of IGF-II mRNA have been found in astrocytomas and glioblastomas. However, similar levels of immunoreactive IGF-II have been reported in both meningiomas and astrocytomas (11, 12). IGF-II levels have not previously been shown to correlate with the degree of malignancy or prognosis of meningiomas.

## Materials and Methods

Tumor pieces were collected at the time of surgery (Department of Neurosurgery, Karolinska Hospital), immediately frozen in liquid nitrogen, and stored at  $-70^{\circ}\text{C}$  until use. For histopathological classification and *in situ* hybridization, the tissue was fixed in 4% paraformaldehyde overnight and embedded in paraffin, as described previously (14).

**Preparation of Probes.** For Northern blots, cDNA probes were used. Human IGF-II (15) and IGFBP-2 (16) cDNAs were labeled with [ $\alpha$ -<sup>32</sup>P]dCTP (Du Medical Scandinavia AB, Sollentuna Sweden) by Multi-Prime Incorporation kit (Amersham Corp., Buckinghamshire, England) to  $1 \times 10^9$  cpm/ $\mu\text{g}$ . Oligonucleotide probes with sequences complementary to human mRNAs encoding IGF-II (nucleotides 407–451; Ref. 15), IGFBP-2 (nucleotides 434–478; Ref. 16), and an IGF-II sense probe (nucleotides 407–451; Ref. 15) were used for *in situ* hybridization. The oligonucleotides were labeled at the 3' end with [ $\alpha$ -<sup>35</sup>S]dATP (Du Medical) using terminal deoxynucleotidyl-transferase (Amersham) to a specific activity of  $1-4 \times 10^9$  cpm/ $\mu\text{g}$ .

**Isolation of RNA and Northern Analysis.** Total RNA was extracted from 68 frozen tumors in a single-step method using acid guanidinium thiocyanate-phenol-chloroform extraction (17). Tumor pieces were pulverized in liquid nitrogen and homogenized in denaturing solution. Fifteen  $\mu\text{g}$  of total RNA were electrophoresed in 1.2% agarose gels containing formaldehyde and transferred to nylon membranes (Zeta-Probe GT; Bio-Rad, Sundbyberg, Sweden). Hybridization was performed at  $42^{\circ}\text{C}$  overnight in 50% deionized formamide,  $5 \times \text{SSC}$  ( $1 \times \text{SSC}$ : 0.15 M NaCl, 0.015 M sodium citrate),  $10 \times$  Denhardt's solution (0.02% polyvinylpyrrolidone, 0.02% BSA, and 0.02% Ficoll), 1% SDS, 50 mM sodium phosphate and 100  $\mu\text{g}/\text{ml}$  denatured salmon sperm DNA (Sigma Chemical Corp., St. Louis, MO), followed by washing at  $60^{\circ}\text{C}$  in  $0.1 \times \text{SSC}$  and 0.1% SDS. Autoradiography was carried out at  $-70^{\circ}\text{C}$  overnight. Northern blots were controlled, prior to and following the analysis with IGF-II and IGFBP-2, with a probe for glyceraldehyde-3-phosphate dehydrogenase, to assess levels of loading and the degree of mRNA degradation (data not shown).

**In Situ Hybridization.** Five- $\mu\text{m}$  paraffin-embedded sections were prepared and mounted on Probe On<sup>+</sup> slides (Fisher Scientific, Pittsburgh, PA). The sections were deparaffinized in xylene (two times for 5 min each) and rehydrated in 99, 95, and 70% ethanol before proteinase K treatment (10  $\mu\text{g}/\text{ml}$  in PBS) for 10 min at  $37^{\circ}\text{C}$ . After rinsing in PBS, the sections were dehydrated again before hybridization. The tissues were hybridized according to published procedures (18). Briefly, the sections were covered with a hybridization buffer containing 50% formamide,  $4 \times \text{SSC}$ ,  $1 \times$  Denhardt's solution, 1% sarcosyl,

Received 3/12/97; accepted 5/15/97.

The costs of publication of this article were defrayed in part by the payment of page charges. This article must therefore be hereby marked *advertisement* in accordance with 18 U.S.C. Section 1734 solely to indicate this fact.

<sup>1</sup> This study was supported by the Swedish Cancer Foundation, the Swedish Medical Research Council, Swedish Society for Medical Research, Swedish Society of Medicine, and Stockholm Cancer Society. M. S. is the recipient of the Ireland award, a National Alliance for Research on Schizophrenia and Depression Established Investigator Award.

<sup>2</sup> To whom requests for reprints should be addressed. Phone: 46-8-51776524; Fax: 46-8-51776521.

<sup>3</sup> The abbreviations used are: IGF, insulin-like growth factor; IGFBP, IGF binding protein; LI, labeling index.

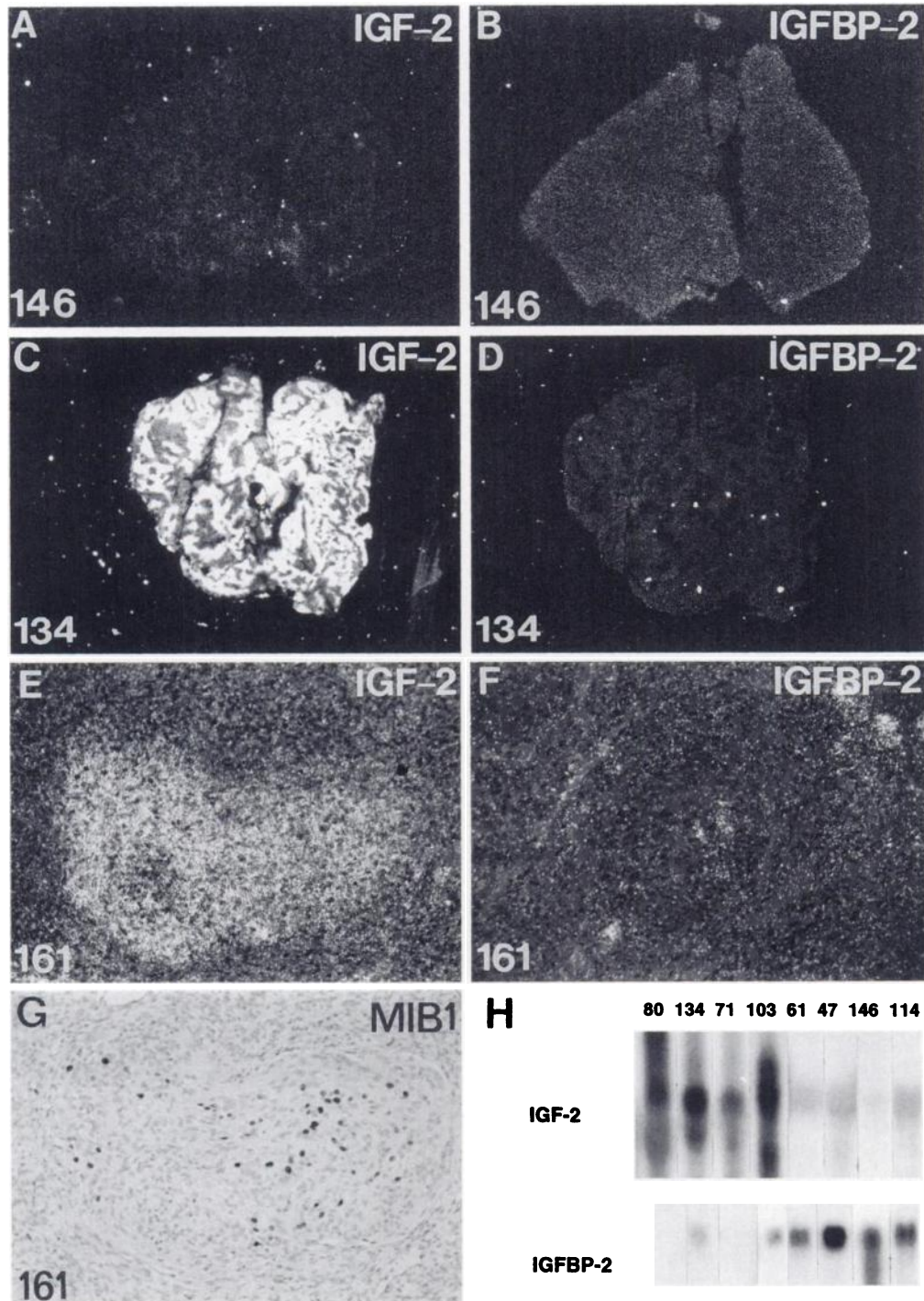


Fig. 1. Dark-field *in situ* hybridization (A–F), immunohistochemical analysis (G), and Northern blot analysis (H) of sporadic meningiomas. In A–D, autoradiographs of paraffin-embedded tumor sections hybridized to oligonucleotide probes are shown. Note strong labeling of IGF-II mRNA in case 134, whereas in case 146, a higher level of IGFBP-2 is observed. Note also non-uniform labeling of IGF-II mRNA in case 134, with IGFBP-2 labeling in a uniform but nonoverlapping pattern. IGF-II (E) and IGFBP-2 (F) emulsion photomicrographs are shown for case 161. In G, immunostaining with MIB1/Ki67 is shown for case 161. Note overlapping distribution pattern for MIB1/Ki67 immunostaining and IGF-II mRNA labeling, whereas the IGFBP-2 mRNA labeling surrounds the area with intense IGF-II labeling. In H, multiple transcripts of IGF-II mRNA are seen following hybridization to cDNA probes. Note that four tumors (80, 134, 71, and 103) predominantly express IGF-II, whereas four (61, 47, 146, and 114) express mainly IGFBP-2. E–G,  $\times 650$ .

0.02 M phosphate buffer (pH 7.0), 10% dextran sulfate (Pharmacia Biotech), 500  $\mu\text{g/ml}$  heat-denatured salmon sperm DNA (Sigma), and 200 mM DTT and  $1 \times 10^7$  cpm/ml of one of the labeled probes. The slides were placed in a box humidified with 50% formamide and  $4 \times$  SSC and incubated for 16–18 h at  $42^\circ\text{C}$ . After hybridization the sections were sequentially rinsed in four changes of  $1 \times$  SSC at  $55^\circ\text{C}$  for 60 min and then dehydrated in 60 and 95% ethanol. After air drying, the sections were exposed to Hyperfilm  $\beta$ -max X-ray film (Amersham), followed by dipping in NTB2 nuclear track emulsion (Kodak, Rochester, NY). After exposure at  $4^\circ\text{C}$  for 2–30 days, slides were developed

in Kodak D19 for 3 min and fixed in Kodak 3000 A for 6 min. After rinsing, the sections were mounted in glycerol-phosphate buffer and analyzed in a Zeiss Axiophot microscope (Carl Zeiss, Oberkochen, Germany) equipped for dark-field illumination.

**Immunocytochemistry.** Tissues were prepared as described for *in situ* hybridization. The sections were microwave irradiated (two times for 5 min each) in 10 mM citrate buffer and washed in Tris-buffered saline. Endogenous peroxidase was blocked by 0.7%  $\text{H}_2\text{O}_2$  in PBS for 30 min. The sections were incubated with normal BSA (4%), drained off, and incubated with MIB1 (a

Table 1 Characteristics of 16 primary meningiomas

Patient no.	Histology	Age at onset/Sex	IGF-2/IGFBP-2	MIB1/Ki-67 <sup>a</sup>			Follow-up <sup>b</sup>
				Min	Mean	Max	
38	Anaplastic	76/F	+++	<2	8	22	†
46	Anaplastic	30/F	+++	<2	14	36	†
71	Anaplastic	64/F	+++	3	3	3	R
80	Anaplastic	35/M	+++	<2	<2	2.5	†
103	Transitional <sup>c</sup>	64/M	+++	<2	<2	<2	†
117	Transitional <sup>c</sup>	53/F	+++	<2	<2	<2	R
134	Meningiothelial <sup>c</sup>	72/M	+++	<2	4	20	L
161	Meningiothelial <sup>c</sup>	52/M	+++	<2	2	5.4	L
47	Transitional	65/F	+/+	<2	<2	<2	NR
61	Meningiothelial	69/F	+++	5.4	5.4	5.4	NR
75	Transitional	75/F	+++	<2	<2	<2	NR
102	Fibroblastic	42/F	+++	<2	<2	<2	NR
114	Fibroblastic	46/F	+++	<2	<2	<2	NR
146	Fibroblastic	64/F	+++	<2	<2	<2	NR
163	Fibroblastic	75/M	++++	<2	<2	<2	NR
167	Transitional	61/F	+++	3	3	3	NR

<sup>a</sup> MIB1/Ki-67, growth fraction labeling index (%); Min, minimum; Max, maximum.

<sup>b</sup> †, dead from tumor disease; R, recurrence of tumor; L, lost to follow-up; NR, no signs of recurrence.

<sup>c</sup> Atypical.

mouse monoclonal antibody specific for the Ki-67 nuclear antigen; Immunotech, S.A., Marseille, France; 1:100) at 4°C overnight. After washing, the sections were incubated with a biotinylated horse anti-mouse secondary antibody (Vector Laboratories, Burlingame, CA; 1:200) for 30 min. Visualization was by an avidin-peroxidase reaction using diaminobenzidine tetrahydrochloride (1 mg/ml; DAKO Corp., Glostrup, Denmark). Sections were counterstained with Gills III hematoxyline, dehydrated in ethanol and xylene, and mounted in Eukit (O. Kindler GmbH and Co., Freiburg, Germany). Sections were analyzed in a Zeiss Axiophot microscope. MIB1/Ki67 LI was assessed by counting a stratified random sample obtained using a grid in the eyepiece. A minimum of 200 cells were counted. Sections immunostained for the progesterone receptor were microwave irradiated (three times for 5 min each) in 10 mM citrate buffer and washed in Tris-buffered saline before incubation with the primary antibody (PR10A9; Immunotech; 1:100). The secondary antibody and the visualization proceeding was the same as above.

## Results and Discussion

We analyzed 68 sporadic meningiomas for IGF-II and IGFBP-2 expression using Northern analysis. Variable levels of expression of both IGF-II mRNA and IGFBP-2 mRNA were observed (Fig. 1). In many tumors, there was an inverse correlation between the levels of IGF-II and IGFBP-2 mRNA so that high levels of IGF-II mRNA were accompanied by very low levels of IGFBP-2 mRNA or *vice versa* (Table 1). In some of the tumors, multiple transcripts of the *IGF-II* gene were seen (Fig. 1H). This may be due to initiation of transcription at several promoters of the *IGF-II* gene, resulting in several mRNA species that contain identical coding regions but different 5'-terminal noncoding exons (3). We found a subset of eight tumors that had an exceptionally high IGF-II mRNA level combined with low IGFBP-2 mRNA levels. These tumors had all been classified as anaplastic (four) or atypical (four) in the preceding histopathological examination (Table 1). In fact, all anaplastic and/or atypical meningiomas (8 of 68) could be identified by screening for a high IGF-II:IGFBP-2 mRNA ratio. The remaining 60 cases were meningiomas with lower malignancy grade (grade I, according to the WHO classification). Interestingly, 14 of these tumors showed high IGF-II and high IGFBP-2 mRNA levels without any sign of anaplasia. Eight tumors with a low ratio of IGF-II:IGFBP-2 mRNA were analyzed further, together with the high IGF-II:IGFBP-2 mRNA ratio group.

To assess the uniformity of expression within these 16 tumors, we used *in situ* hybridization. In particular, the IGF-II mRNA distribution pattern varied considerably from sample to sample. We observed some tumors with quite uniform labeling all through the tissue (Fig. 1A), whereas others had distinct foci with strong labeling surrounded

by areas with no or a very low level of labeling (Fig. 1C). In contrast, the pattern of IGFBP-2 expression was more uniform (Fig. 1, B and D). In tumors with regions that labeled intensely with the IGF-II probe, IGFBP-2 labeling was nonoverlapping, with most abundant labeling surrounding the IGF-II foci (Fig. 1, E and F). Among patients with a high ratio of IGF-II:IGFBP-2 mRNA levels in their tumors, there was an equal number of males and females (four of four), with a mean age at diagnosis of 55.8, whereas patients with a low ratio were mostly females (46 of 60), with an average age at diagnosis of 55.3. These findings are in accordance with established epidemiological data (19).

We also estimated the growth fraction MIB1/Ki67 LI. A higher MIB1/Ki67 LI has been shown to be correlated with meningiomas displaying a higher histological grade as a sign of increasing degree of anaplasia and atypical histopathology (20, 21). Although the two most intensely labeled tumors were anaplastic, the MIB1/Ki67 LI was in fact not significantly higher in tumors with a high ratio of IGF-II:IGFBP-2 (assessed in areas with the highest labeling in all cases) than in tumors producing higher levels of IGFBP-2 than IGF-II mRNA (Table 1). MIB1/Ki67 labeling in the tumors was found to be homogeneous in all benign meningiomas, in two of four atypical tumors, and in one of four anaplastic meningiomas. The remaining tumors showed a heterogeneous labeling (two atypical and three anaplastic meningiomas; Table 1; Fig. 1G), with areas displaying low MIB1/Ki67 LI and other areas with high LI. The areas with high LI also showed high levels of IGF-II mRNA (Fig. 1E). Nevertheless, one of the four anaplastic and two of the four atypical meningiomas had a low MIB1/Ki67 LI, making this measure less reliable than the IGF-II:IGFBP-2 mRNA ratio.

Furthermore, the absence of progesterone receptors has been associated with higher histological grade, and anaplastic and atypical meningiomas are reported to be frequently progesterone receptor negative (20, 21). We processed sections from the 16 selected tumors for progesterone receptor immunostaining and found labeling of variable intensity among these 16 tumors. However, the degree of labeling showed no clear correlation to the ratio of IGF-II:IGFBP-2 mRNA levels, neither was there any clear correlation to the histopathological malignancy grades (data not shown). All tumors were carefully analyzed for alterations on chromosome 22, because monosomy and deletions on this chromosome are observed frequently in meningiomas (14). No difference in chromosome 22 alterations was observed between patients with high (6 of 8 with monosomy) or low (48 of 60 with monosomy) IGF-II:IGFBP-2 mRNA ratio.

In a clinical 5-year follow-up of the patients with high IGF-II:IGFBP-2 mRNA ratio, four died from the tumor, two had recurrence, and two were lost to follow-up. Among the group with low IGF-II:IGFBP-2 mRNA ratio, no tumor-associated death was observed, and no recurrences were seen.

The limited correlation between tumor recurrence and histopathological criteria has created a need for molecular approaches to predict biological behavior of meningiomas (22). We suggest that a high IGF-II:IGFBP-2 mRNA ratio is a sign of biologically aggressive behavior in meningiomas, which may fulfill the need of a molecular marker. The detection of this sign should, therefore, influence the treatment strategy regarding operative radically adjuvant therapy and postoperative follow-up.

### Acknowledgments

We thank Ingegerd Fransson and Mia Nilsson for technical assistance.

### References

- Russel, D. S., and Rubinstein, L. J. Pathology of Tumors of the Nervous System, Ed. 5, pp. 834–837. Baltimore: Williams & Wilkins, 1989.
- Kepes, J. J. Meningiomas: Biology, Pathology and Differential Diagnosis. New York: Masson Publishing, Inc., 1982.
- de Pagter-Holthuisen, P., van der Kammen, R. A., Jansen, M., van Schajk, F. M. A., and Sussenbach, J. S. Differential expression of the human insulin-like growth factor II gene. Characterization of the IGF-II mRNAs and an mRNA encoding a putative IGF-II-associated protein. *Biochem. Biophys. Acta*, 950: 282–295, 1988.
- Werner, H., and LeRoith, D. The role of the insulin-like growth factor system in the human cancer. *Adv. Cancer Res.*, 68: 183–223, 1996.
- Rogler, C. E., Yang, D., Rossetti, L., Donohoe, J., Alt, E., Chang, C. J., Rosenfeld, R., Neely, K., and Hintz, R. Altered body composition and increased frequency of diverse malignancies in insulin-like growth factor-II transgenic mice. *J. Biol. Chem.*, 269: 13779–13784, 1994.
- Cullen, K. J., Lippman, M. E., Chow, D., Hill, S., Rosen, N., and Zwiebel, J. A. Insulin-like growth factor-II overexpression in MCF-7 cells induces phenotypic changes associated with malignant progression. *Mol. Endocrinol.*, 6: 91–100, 1992.
- Logan, A., Gonzalez, A.-M., Hill, D. J., Berry, M., Gregson, O. A., and Baird, A. Coordinated pattern of expression and localization of insulin-like growth factor-II (IGF-II) and IGF-binding protein-2 in the adult rat brain. *Endocrinology*, 135: 2255–2264, 1994.
- Lesniak, M. A., Hill, J. M., Kiess, W., Rojeski, M., Pert, C. B., and Roth, J. Receptors for insulin-like growth factors I and II: autoradiographic localization in rat brain and comparison to receptors for insulin. *Endocrinology*, 123: 2089–2099, 1988.
- Clemmons, D. R. Insulin-like growth factor binding proteins: roles in regulating IGF physiology. *J. Dev. Physiol.*, 15: 105–110, 1991.
- Lichter, L., Kurpakus, M. A., and Gurney, M. E. Differential expression of insulin-like growth factor II in human meningiomas. *Neurosurgery*, 29: 405–410, 1991.
- Hultberg, B. M., Haselbacher, G., Nielsen, F. C., Wulff, B. S., and Gammeltoft, S. Gene expression of insulin-like growth factor II in human intracranial meningioma. *Cancer (Phila.)*, 72: 3282–3286, 1993.
- Antoniades, H. N., Galanopoulos, T., Neville-Golden, J., and Maxwell, M. Expression of insulin-like growth factors I and II and their receptor mRNAs in primary human astrocytomas and meningiomas: *in vivo* studies using *in situ* hybridization and immunocytochemistry. *Int. J. Cancer*, 50: 215–222, 1992.
- Sandberg, A.-C., Engberg, C., Lake, M., von Holst, H., and Sara, V. R. The expression of insulin-like growth factor I and insulin-like growth factor II genes in the human fetal and adult brain and in glioma. *Neurosci. Lett.*, 93: 114–119, 1988.
- Rutledge, M. H., Xie, Y.-G., Han, F.-Y., Peyrard, M., Collins, V. P., Nordenskjöld, M., and Dumanski, J. P. Deletions on chromosome 22 in sporadic meningioma. *Genes Chromosomes Cancer*, 10: 122–130, 1994.
- Bell, G. I., Merryweather, J. P., Sanchez-Pescador, R., Stempien, M. M., Priestley, L., Scott, J., and Rall, L. B. Sequence of a cDNA clone encoding human preproinsulin-like growth factor II. *Nature (Lond.)*, 310: 775–777, 1984.
- Binkert, C., Landwehr, J., Mary, J.-L., Schwander, J., and Heinrich, G. Cloning, sequence analysis and expression of a cDNA encoding a novel insulin-like growth factor binding protein (IGFBP-2). *EMBO J.*, 8: 2497–2502, 1989.
- Chomczynski, P., and Sacchi, N. Single-step method of RNA isolation by acid guanidinium thiocyanate-phenol-chloroform extraction. *Anal. Biochem.*, 162: 156–159, 1987.
- Schalling, M., Franco-Cereceda, A., Hensen, A., Dagerlind, Å., Seroogy, K., Persson, H., Hökfelt, T., and Lundberg, J. M. Neuropeptide Y and catecholamine synthesizing enzymes and their mRNAs in rat sympathetic neurons and adrenal glands: studies on expression, synthesis and axonal transport after pharmacological and experimental manipulations using hybridization techniques and radioimmunoassay. *Neuroscience*, 41: 753–766, 1991.
- Longstreth, W. T., Jr., Dennis, L. K., McGuire, V. M., Drangsholt, M. T., and Koepsell, T. D. Epidemiology of intracranial meningioma. *Cancer (Phila.)*, 72: 639–648, 1993.
- Nagashima, G., Aoyagi, M., Wakimoto, H., Tamaki, M., Ohno, K., and Hirakawa, K. Immunohistochemical detection of progesterone receptors and the correlation with Ki-67 labeling indices in paraffin-embedded sections of meningiomas. *Neurosurgery*, 37: 478–483, 1995.
- Bouillot, P., Pellissier, J.-F., Devictor, B., Graziand, N., Bianco, N., Grisoli, F., and Figarella-Branger, D. Quantitative imaging of estrogen and progesterone receptors, estrogen-regulated protein, and growth fraction: immunocytochemical assays in 52 meningiomas. *J. Neurosurg.*, 81: 765–773, 1994.
- Wilson, C. B. Meningiomas: genetics, malignancy, and the role of radiation in induction and treatment. *J. Neurosurg.*, 81: 666–675, 1994.

# Cancer Research

The Journal of Cancer Research (1916–1930) | The American Journal of Cancer (1931–1940)

## A High Ratio of Insulin-like Growth Factor II/Insulin-like Growth Factor Binding Protein 2 Messenger RNA as a Marker for Anaplasia in Meningiomas

Ann-Christin Sandberg Nordqvist, Myriam Peyrard, Helena Pettersson, et al.

*Cancer Res* 1997;57:2611-2614.

**Updated version** Access the most recent version of this article at:  
<http://cancerres.aacrjournals.org/content/57/13/2611>

**E-mail alerts** [Sign up to receive free email-alerts](#) related to this article or journal.

**Reprints and Subscriptions** To order reprints of this article or to subscribe to the journal, contact the AACR Publications Department at [pubs@aacr.org](mailto:pubs@aacr.org).

**Permissions** To request permission to re-use all or part of this article, use this link <http://cancerres.aacrjournals.org/content/57/13/2611>. Click on "Request Permissions" which will take you to the Copyright Clearance Center's (CCC) Rightslink site.