

Microsatellite Instability of Germ Cell Tumors Is Associated with Resistance to Systemic Treatment¹

Frank Mayer, Ad J. M. Gillis, Winand Dinjens, J. Wolter Oosterhuis, Carsten Bokemeyer, and Leendert H. J. Looijenga²

Pathology/Laboratory for Exp. Patho-Oncology [F. M., A. J. M. G., J. W. O., L. H. J. L.] and Pathology/Molecular Diagnostics [W. D.], University Hospital Rotterdam/Daniel, Josephine Nefkens Institute, 3000 DR Rotterdam, the Netherlands, and Department of Oncology, Hematology, Immunology, and Rheumatology, University of Tuebingen Medical Center, Tuebingen 72076, Germany [F. M., C. B.]

Abstract

Systemic cisplatin-based chemotherapy cures $\geq 90\%$ of patients with metastatic germ cell tumors (GCTs). The biological basis of this exquisite chemo-sensitivity and the resistant phenotype encountered in 10–15% of patients with GCT is yet unclear. A defective mismatch repair pathway leading to microsatellite instability (MSI) has been related to resistance to cytotoxic drugs. We investigated 100 unselected GCTs and 11 clinically defined chemotherapy-resistant GCTs for MSI using 8 mono- or dinucleotide markers and the presence of the mismatch repair factors MLH1, MSH2, and MSH6 by immunohistochemistry. The resistant tumors, both chemo-naïve ($n = 8$) and pretreated ($n = 3$), showed a significantly higher incidence of MSI compared with the unselected series (45 versus 6% in at least one locus and 36 versus 0% in ≥ 2 of 8 loci, both $P \leq 0.001$). In 5 of all 11 unstable tumors, MSI correlated with immunohistochemical findings. This study demonstrates for the first time a positive correlation between MSI and treatment resistance in GCT.

Introduction

GCTs³ of adults are the most frequent solid tumor of Caucasian males between 20 and 45 years of age (1). On the basis of histological, biological, and clinical differences, GCTs are divided in seminomas and nonseminomas (2). Even in metastatic stages, most patients with GCTs can be cured with multiagent, CDDP-based chemotherapy (Ref. 3, for review). Despite this success, 10–15% of the patients do not achieve a long-lasting remission with the available treatment strategies and eventually die of their disease. Up to now, the biological basis for the exquisite treatment sensitivity of most GCT has not been elucidated. This also accounts for the mechanism of chemotherapy resistance (Ref. 4, for review). Response to CDDP-based chemotherapy of ovarian carcinoma has been related to MSI, *i.e.*, alterations in length of short repetitive sequences of the genome by small deletions or insertions. MSI is caused by genetic or epigenetic changes in genes of the DNA MMR pathway. Several proteins of this pathway have been identified, including MLH1, MSH2, and MSH6 (Ref. 5, for review), whose inactivation might result in MSI. A number of reports deal with MSI in GCT. Although most of them showed a negative result (6–8), one study indicated locus-specific instability (9). Thus far, MSI has not been correlated with treatment resistance of GCT.

Received 2/12/02; accepted 3/22/02.

The costs of publication of this article were defrayed in part by the payment of page charges. This article must therefore be hereby marked *advertisement* in accordance with 18 U.S.C. Section 1734 solely to indicate this fact.

¹ Supported by the Dutch Cancer Society/KWF (A. J. M. G., J. W. O., and L. H. J. L.). Frank Mayer was financially supported by the fellowship program of the European Society of Medical Oncology (ESMO).

² To whom requests for reprints should be addressed, at Pathology/Lab. for Exp. Patho-Oncology, University Hospital Rotterdam/Daniel, Josephine Nefkens Institute, Erasmus University Rotterdam, Building Be, room 430b, P. O. Box 1738, 3000 DR Rotterdam, the Netherlands. Phone: (31) 104088329; Fax: (31) 104088365; E-mail: Looijenga@leph.azr.n.

³ The abbreviations used are: GCT, germ cell tumor; CDDP, *cis*-diamino-dichlorid-platin; MSI, microsatellite instability; MMR, mismatch repair.

Here we report the results of an analysis of the presence of MSI and the related factors MLH1, MSH2, and MSH6 in a large series of unselected GCT and a unique series of treatment-resistant GCT.

Materials and Methods

Patients and Samples. Fresh frozen and formalin-fixed, paraffin-embedded tissue from 100 unselected cases (50 seminomas and 50 nonseminomas), in most cases together with peripheral blood, was collected between 1991 and 2001 in collaboration with urologists and pathologists in the Southwestern part of the Netherlands. These cases were retrieved from the archive of the Laboratory for Experimental Patho-Oncology (Department of Pathology). Complete data on the clinical course were not available of these patients.

The resistant series consisted of 11 patients diagnosed between 1991 and 1998, treated within various trials led by Tübingen University, Germany. Patients were considered refractory, when progression or relapses of the disease occurred despite adequate initial and salvage treatment. The tumors were obtained either at initial diagnosis (*i.e.*, before chemotherapy, $n = 8$) or by resection of a metastatic lesion in relapse ($n = 3$).

Table 1 summarizes the characteristics of the unselected and refractory patients. All cases were reviewed and diagnosed by an experienced pathologist (J. W. O.) according to the WHO classification (2).

DNA Isolation and Microsatellite Analysis. Normal DNA was isolated either from peripheral blood or, if not available, from nontumor tissue specifically dissected from the tissue blocks as described before (10). DNA of fresh-frozen tissue or paraffin-embedded tissue was isolated according to standard procedures as described previously (4). Microsatellite analysis of pairs of normal and tumor DNA was performed as described previously using eight mono- or dinucleotide markers (D2S123, BAT25, BAT26, D5S346, D17S250, BTRII, MSH6, and BAT40) with an input of 50 ng of DNA/PCR reaction (11).

Immunohistochemistry. Paraffin sections of 3- μ m thickness were mounted on APES-coated slides, deparaffinized, and rehydrated. Antigens were unmasked by high temperature/high pressure [120°C, 1.2 bar in Na-citrate 0.01 M (pH 6)]. MLH1, MSH2, and MSH6 were demonstrated using mouse monoclonal antibodies (MHL1: clone G168–15, diluted 1:500; MSH2: clone G219–1129, diluted 1:400; MSH6: clone 44, diluted 1:1000; all BD Biosciences, Alphen aan den Rijn, the Netherlands). The sections were incubated with the primary antibodies overnight at 4°C (MLH1 and MSH2) or room temperature (MSH6). Biotin-labeled rabbit-antimouse immunoglobulins and a biotinylated horseradish peroxidase-Streptavidin complex (both DAKO, Glostrup, Denmark) were applied subsequently for 30 min at room temperature each. Diamino-benzidin was used as chromogen. Normal tonsil and colon tissue served as positive controls. Nuclear staining was scored as “strong,” “weak,” or “absent” compared with lymphocytes as internal positive controls, known to be positive for all markers (12).

Statistical Analysis. The two groups of unselected and refractory GCT were compared for differences in the incidence of MSI overall and by number of unstable loci using a two-sided Fisher’s exact test. Differences were considered significant, when the P was < 0.05 . Differences in time to progression and overall survival between refractory cases with and without MSI were analyzed by a Log-rank test.

Table 1 Baseline patient characteristics^a

	Unselected (n = 100)	Refractory (n = 11)
Median age (years)	32 (14–66)	29 (18–55)
Histology		
Seminoma	50	1
Nonseminoma	50	10
Mixed nonseminoma	29	7
Embryonal carcinoma	7	0
Yolk sac tumor	5	3
Mature teratoma	9	0
Time of tissue sampling		
At initial diagnosis	99	8
After chemotherapy	1	3
Systemic treatment		
Standard PE/PEB/PVB/PEI	NA	11
Salvage high-dose chemotherapy	NA	7
Median time to progression (months)	NA	10 (2–149)
Median overall survival (months)	NA	40 (11–180)

^a P, cisplatin; E, etoposide; B, bleomycin; V, vinblastine; I, ifosfamide; NA, not available.

Table 2 Summary of MSI and immunohistochemical analysis on control and refractory GCT

	Unselected (n = 100)	Refractory (n = 11)	P ^d
MSI	6 (6%)	5 (45%)	0.001 ^b
MSI in 1 of 8 loci	6 (6%)	1 (9%)	0.558 ^b
MSI in ≥2 of 8 loci	0	4 (36%)	<0.001 ^b
IHC ^c negative/weak any marker	3 (3%)	4 (36%)	
hMMLH1	0	4 (36%)	
hMMSH2	2 (2%)	1 (9%)	
hMMSH6	2 (2%)	1 (9%)	
MSI correctly predicted by IHC	2	3	
MSI not predicted by IHC	4	2	
MSI falsely predicted by IHC	1	1	

^a P_s are given for differences between all tumors of the two study groups as determined by a two-sided Fisher's exact test.

^b Analyzing only the nonseminomas of both groups, the P_s are 0.002, 0.508, and <0.001, respectively.

^c IHC, immunohistochemistry.

Results

In total, a series of 111 GCT and matched normal DNA was studied using eight microsatellite markers. Instability was found in 6 of the 100 control GCTs (6%, three seminomas and three nonseminomas), all of them affecting only one locus (four in BAT40, one in MSH6, and one in D17S250). In contrast, the series of refractory GCTs showed MSI in 5 of 11 cases (45%, all nonseminomas), 4 of which were sampled before chemotherapy exposure. This difference was statistically significant ($P = 0.001$; analyzing only nonseminomas: $P = 0.002$). Four of these refractory tumors (three obtained before chemotherapy and one after) showed instability in two or more loci, which was never observed in the unselected series ($P < 0.001$, also for analysis of nonseminomas only). The results are summarized in Table 2, and representative examples of the microsatellite analysis in the refractory GCTs are shown in Fig. 1A. The refractory cases showing MSI and those without were analyzed regarding their progression-free survival and overall survival by the Kaplan-Meier method and compared using the Log-rank test. The microsatellite stable cases had a median progression-free survival time of 6 months compared with 26 months in the group of tumors with MSI ($P = 0.05$; see Fig. 1B); the data for the median overall survival were 21 and 41 months, respectively ($P = 0.43$; data not shown).

All tumors were investigated by immunohistochemistry for the presence of the MLH1, MSH2, and MSH6 proteins. Most cases showed an intense homogeneous nuclear staining of nearly all tumor cells, irrespective of their histology. Three of the 100 (3%) control tumors and 4 of the 11 refractory tumors (36%) showed a markedly reduced signal in any of the three stainings. Examples of tumors with a staining for MSH6 rated as “absent” and “strong” are shown in Fig. 1C, and the results are summarized in Table 2. Of note, one GCT (of the control series) showed instability within the *MSH6* locus with concomitant loss of MSH6 protein. The immunohistochemical findings in this study did only successfully predict the presence of MSI in two of the six unstable control GCTs and in three of the five unstable refractory GCTs. In addition, a “weak/absent” immunohistochemical

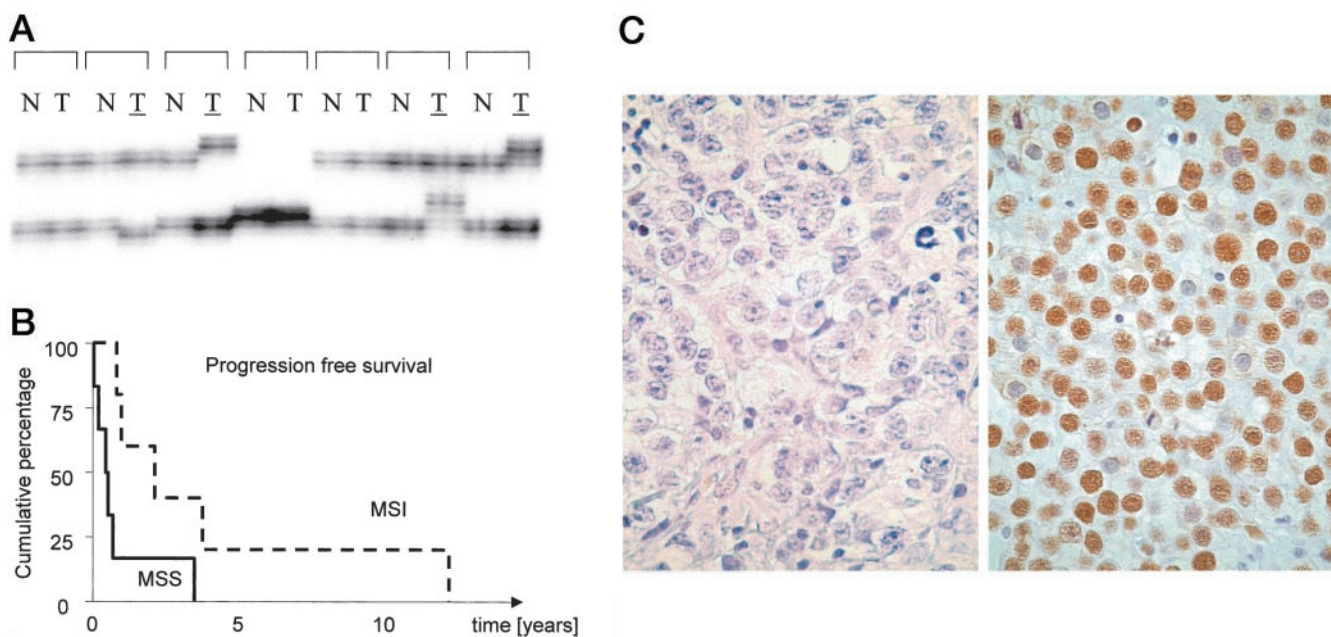


Fig. 1. A, microsatellite analysis on pairs of normal DNA/tumor DNA of seven refractory cases using D2S123 as a marker (the unstable tumors are underlined); B, Kaplan-Meier curve for progression-free survival of patients with refractory tumors with MSI and those with microsatellite stability (MSS). The difference was borderline significant by Log-rank test ($P = 0.05$); C, representative examples of immunohistochemical detection of the MSH6 protein. Left panel, tumor scored “absent” (same case showed MSI in MSH6 locus); right panel, tumor scored “strong.”

finding was found in two GCTs (one control and one refractory) in the absence of MSI.

Discussion

The unique chemo-sensitivity of GCT is poorly understood at the molecular level thus far. We demonstrated recently that the model assuming a high level of wild-type P53 resulting in a low threshold for induction of apoptosis is not correct (4). This particular study also showed that genetic inactivation of P53 is not a major way to induce treatment resistance in GCT as proposed previously (13).

In vitro analyses of cell lines of various origin have suggested a correlation between MSI, MMR, and sensitivity toward CDDP, the key substance of all combination regimens in the systemic treatment of GCT (14, 15). A number of groups has analyzed MSI and the MMR pathway in GCT and found a low rate of instability without correlating the results to clinical outcome (6–9). Our findings confirm these results in a large series, including all different histological subtypes of GCT. However, in a clinically defined group of treatment-resistant GCT, 45% of the tumors showed MSI, most of them in two of the eight investigated markers, a feature never encountered in any of the control tumors. A correlation between MSI and treatment resistance can be explained by two different mechanisms (Ref. 16, for review): (a) the MSI renders the genome of the cancer cell prone to harbor secondary mutations, which could be responsible for the resistant phenotype; or (b) MMR factors could directly be involved in induction of apoptosis (17). This could result in resistance to apoptosis independent from the presence of actual MSI. It remains to be determined to what extent these two mechanisms contribute to the resistance of GCT. It is important to note that the majority of the unstable refractory GCTs investigated in this study was sampled before exposure to chemotherapy. Our data differ in this feature from *in vitro* data and a study on ovarian cancer, where MSI was induced by CDDP-based treatment (14, 18). To study the biological relevance of MSI, we compared the progression-free and overall survival between the refractory patients with and without MSI. The shorter progression-free survival in the subgroup of refractory tumors without MSI suggests a different clinical behavior of refractory tumors depending on the underlying resistance mechanism. A similar observation was made in colon cancer (19). The difference in behavior may be explained by a higher level of resistance mediated by mechanisms other than MSI in these tumors. The lack of a difference in overall survival might be caused by accumulation of secondary mutations in tumors with MSI leading to a more aggressive phenotype in the later course of the disease. However, with the limited number of patients in the refractory group, these considerations remain speculative at this point.

Immunohistochemical demonstration of MMR factors has been applied successfully to predict MSI in colon cancer (20). In contrast, low protein levels of MMR factors did not correlate with MSI in cell lines derived from gastric carcinoma (21). Our findings indicate that assessing MLH1, MSH2, and MSH6 by immunohistochemistry is not sensitive and specific enough to predict MSI in GCT. This difference to the situation in colon cancer could be related to a more prominent role of other MMR factors, like PMS1 and PMS2, in the development of MSI in GCT, as has been suggested for prostate cancer (22). However, the data suggest a reduced protein level of specific MMR factors as an explanation of MSI at least in some GCT.

In summary, we demonstrate a correlation between chemotherapy resistance and MSI in GCT. The results offer the first plausible explanation for the clinical behavior of refractory GCT. Furthermore, analyzing MSI shows promise to predict treatment response based on

characteristics of the primary tumor in a significant number of cases. In this regard, the findings have to be validated prospectively.

Acknowledgments

We thank Maxime Look (Department of Medical Oncology, University Hospital Rotterdam/Daniel) and Jochen Mayer for their support on the statistical analysis.

References

- Adami, H. O., Bergström, R., Möhner, M., Zatonski, W., Storm, H., Ekblom, A., Tretli, S., Teppo, L., Ziegler, H., Rahu, M., Gurevicius, R., and Stengrevics, A. Testicular cancer in nine northern European countries. *Int. J. Cancer*, 59: 33–38, 1994.
- Mostofi, F. K., and Sesterhenn, I. A. (eds.). *Histological Typing of Testis Tumours*, Ed. 2, p. 132. Berlin: Springer, 1998.
- Morris, M. J., and Bosl, G. J. High-dose chemotherapy as primary treatment for poor-risk germ-cell tumors: the Memorial Sloan-Kettering experience (1988–1999). *Int. J. Cancer*, 83: 834–838, 1999.
- Kersemackers, A. M. F., Mayer, F., Molier, M., Van Weeren, P. C., Oosterhuis, J. W., Bokemeyer, C., and Looijenga, L. H. J. Role of P53 and MDM2 in treatment response of human germ cell tumors. *J. Clin. Oncol.*, 20: 1551–1561, 2002.
- Claij, N., and te Riele, H. Microsatellite instability in human cancer: a prognostic marker for chemotherapy? *Exp. Cell Res.*, 246: 1–10, 1999.
- Lothe, R. A., Peltomäki, P., Tommerup, N., Fosså, S. D., Stenwig, A. E., Borresen, A. L., and Nesland, J. M. Molecular genetic changes in human male germ cell tumors. *Lab. Invest.*, 73: 606–614, 1995.
- Peltomäki, P., Lothe, R. A., Aaltonen, L. A., Pylkkanen, L., Nystrom-Lahti, M., Seruca, R., David, L., Holm, R., Ryberg, D., Haugen, A. *et al.* Microsatellite instability is associated with tumors that characterize the hereditary non-polyposis colorectal carcinoma syndrome. *Cancer Res.*, 53: 5853–5855, 1993.
- Devouassoux-Shisheboran, M., Mauduit, C., Bouvier, R., Berger, F., Bouras, M., Droz, J. P., and Benahmed, M. Expression of hMLH1 and hMSH2 and assessment of microsatellite instability in testicular and mediastinal germ cell tumours. *Mol. Hum. Reprod.*, 7: 1099–1105, 2001.
- Murty, V. V. S., Li, R. G., Mathew, S., Reuter, V. E., Bronson, D. L., Bosl, G. J., and Chaganti, R. S. K. Replication error-type genetic instability at 1q42–43 in human male germ cell tumors. *Cancer Res.*, 54: 3983–3985, 1994.
- Looijenga, L. H. J., Gillis, A. J. M., Verkerk, A. J. M. H., Van Putten, W. L. J., and Oosterhuis, J. W. Heterogeneous X-inactivation in human female full term placenta's. *Am. J. Hum. Genet.*, 64: 1445–1452, 1999.
- Boland, C. R., Thibodeau, S. N., Hamilton, S. R., Sidransky, D., Eshleman, J. R., Burt, R. W., Meltzer, S. J., Rodriguez-Bigas, M. A., Fodde, R., Ranzani, G. N., and Srivastava, S. A National Cancer Institute Workshop on Microsatellite Instability for cancer detection and familial predisposition: development of international criteria for the determination of microsatellite instability in colorectal cancer. *Cancer Res.*, 58: 5248–5257, 1998.
- Parc, Y. R., Halling, K. C., Wang, L., Christensen, E. R., Cunningham, J. M., French, A. J., Burgart, L. J., Price-Troska, T. L., Roche, P. C., and Thibodeau, S. N. HMSH6 alterations in patients with microsatellite instability-low colorectal cancer. *Cancer Res.*, 60: 2225–2231, 2000.
- Houldsworth, J., Xiao, H., Murty, V. V., Chen, W., Ray, B., Reuter, V. E., Bosl, G. J., and Chaganti, R. S. Human male germ cell tumor resistance to cisplatin is linked to TP53 gene mutation. *Oncogene*, 16: 2345–2349, 1998.
- Aebi, S., Kurdi-Haidar, B., Gordon, R., Cenni, B., Zheng, H., Fink, D., Christen, R. D., Boland, C. R., Koi, M., Fishel, R., and Howell, S. B. Loss of DNA mismatch repair in acquired resistance to cisplatin. *Cancer Res.*, 56: 3087–3090, 1996.
- Fink, D., Zheng, H., Nebel, S., Norris, P. S., Aebi, S., Lin, T. P., Nehme, A., Christen, R. D., Haas, M., MacLeod, C. L., and Howell, S. B. *In vitro* and *in vivo* resistance to cisplatin in cells that have lost DNA mismatch repair. *Cancer Res.*, 57: 1841–1845, 1997.
- Lage, H., and Dietel, M. Involvement of the DNA mismatch repair system in antineoplastic drug resistance. *J. Cancer Res. Clin. Oncol.*, 125: 156–165, 1999.
- Hardman, R. A., Afshari, C. A., and Barrett, J. C. Involvement of mammalian MLH1 in the apoptotic response to peroxide-induced oxidative stress. *Cancer Res.*, 61: 1392–1397, 2001.
- Watanabe, Y., Koi, M., Hemmi, H., Hoshai, H., and Noda, K. A change in microsatellite instability caused by cisplatin-based chemotherapy of ovarian cancer. *Br. J. Cancer*, 85: 1064–1069, 2001.
- Messerini, L., Ciantelli, M., Baglioni, S., Palomba, A., Zampì, G., and Papi, L. Prognostic significance of microsatellite instability in sporadic mucinous colorectal cancers. *Hum. Pathol.*, 30: 629–634, 1999.
- Marcus, V. A., Madlensky, L., Gryfe, R., Kim, H., So, K., Millar, A., Temple, L. K., Hsieh, E., Hiruki, T., Narod, S., Bapat, B. V., Gallinger, S., and Redston, M. Immunohistochemistry for hMLH1 and hMSH2: a practical test for DNA mismatch repair-deficient tumors. *Am. J. Surg. Pathol.*, 23: 1248–1255, 1999.
- Shin, K. H., and Park, J. G. Microsatellite instability is associated with genetic alteration but not with low levels of expression of the human mismatch repair proteins hMSH2 and hMLH1. *Eur. J. Cancer*, 36: 925–931, 2000.
- Chen, Y., Wang, J., Fraig, M. M., Metcalf, J., Turner, W. R., Bissada, N. K., Watson, D. K., and Schweinfest, C. W. Defects of DNA mismatch repair in human prostate cancer. *Cancer Res.*, 61: 4112–4121, 2001.

Cancer Research

The Journal of Cancer Research (1916–1930) | The American Journal of Cancer (1931–1940)

Microsatellite Instability of Germ Cell Tumors Is Associated with Resistance to Systemic Treatment

Frank Mayer, Ad J. M. Gillis, Winand Dinjens, et al.

Cancer Res 2002;62:2758-2760.

Updated version Access the most recent version of this article at:
<http://cancerres.aacrjournals.org/content/62/10/2758>

Cited articles This article cites 20 articles, 9 of which you can access for free at:
<http://cancerres.aacrjournals.org/content/62/10/2758.full#ref-list-1>

Citing articles This article has been cited by 10 HighWire-hosted articles. Access the articles at:
<http://cancerres.aacrjournals.org/content/62/10/2758.full#related-urls>

E-mail alerts [Sign up to receive free email-alerts](#) related to this article or journal.

Reprints and Subscriptions To order reprints of this article or to subscribe to the journal, contact the AACR Publications Department at pubs@aacr.org.

Permissions To request permission to re-use all or part of this article, use this link
<http://cancerres.aacrjournals.org/content/62/10/2758>.
Click on "Request Permissions" which will take you to the Copyright Clearance Center's (CCC) Rightslink site.