

Stem Cell Factor Receptor (c-KIT) Codon 816 Mutations Predict Development of Bilateral Testicular Germ-Cell Tumors

Leendert H. J. Looijenga,¹ Hubert de Leeuw,¹ Monique van Oorschot,¹ Ruud J. H. L. M. van Gorp,¹ Hans Stoop,¹ Ad J. M. Gillis,¹ Carlos A. de Gouveia Brazao,² Rob F. A. Weber,² Wim J. Kirkels,³ Thamar van Dijk,⁴ Marieke von Lindern,⁴ Peter Valk,⁴ Geczy Lajos,⁵ Edit Olah,⁵ Jahn M. Nesland,⁶ Sophie D. Fosså,⁶ and J. Wolter Oosterhuis¹

¹Pathology/Laboratory for Experimental Patho-Oncology, Erasmus MC, University Medical Center Rotterdam, Daniel den Hoed Cancer Center, Josephine Nefkens Institute, Rotterdam, the Netherlands; ²Andrology, ³Department of Urology, and ⁴Department of Hematology, Erasmus MC, Rotterdam, the Netherlands; ⁵Departments of Chemotherapy C and Molecular Genetics, National Institute of Oncology, Budapest, Hungary; ⁶Department of Pathology and Clinical Research, the Norwegian Radium Hospital, Oslo, Norway

ABSTRACT

Testicular germ-cell tumors (TGCTs) of adolescents and adults originate from intratubular germ cell neoplasia (ITGCN), which is composed of the malignant counterparts of embryonal germ cells. ITGCN cells are characterized, among others, by the presence of stem cell factor receptor c-KIT. Once established, ITGCN will always progress to invasiveness. Approximately 2.5–5% of patients with a TGCT will develop bilateral disease and require complete castration, resulting in infertility, a need for lifelong androgen replacement, and psychological stress. To date, the only way to predict a contralateral tumor is surgical biopsy of the contralateral testis to demonstrate ITGCN. We did a retrospective study of 224 unilateral and 61 proven bilateral TGCTs (from 46 patients, in three independently collected series in Europe) for the presence of activating c-KIT codon 816 mutations. A c-KIT codon 816 mutation was found in three unilateral TGCT (1.3%), and in 57 bilateral TGCTs (93%; $P < 0.0001$). In the two wild-type bilateral tumors for which ITGCN was available, the preinvasive cells contained the mutation. The mutations were somatic in origin and identical in both tumors. We conclude that somatic activating codon 816 c-KIT mutations are associated with development of bilateral TGCT. Detection of c-KIT codon 816 mutations in unilateral TGCT identifies patients at risk for bilateral disease. These patients may undergo tailored treatment to prevent the development of bilateral disease, with retention of testicular hormonal function.

INTRODUCTION

TGCTs⁷ of adolescents and adults, the seminomas and nonseminomas (1), are the most frequent malignancies in Caucasian males 15–40 years of age (2). Several risk factors have been reported, including family history, undescended testis, and a previous TGCT (see Ref. 3 for review). The initiating event, leading to ITGCN, also known as carcinoma *in situ* (4), occurs during intrauterine development (5, 6). ITGCN cells indeed show characteristics of embryonic germ cells, *i.e.*, PGCs/gonocytes, including the presence of the stem cell factor receptor c-KIT (7) and OCT3/4 (POU5F1; Ref. 8).

Between 2.5 and 5% of TGCT patients will develop contralateral disease. Approximately half of the second tumors are diagnosed within the first 5 years after the initial diagnosis. However, ~25% of patients present with the second tumor 10 years after diagnosis of the first, and the latency period can be up to 20 years (9, 10). This

illustrates the need for a long follow-up of all TGCT patients. To date, no predictor for risk of bilateral TGCT is available, except an open surgical biopsy for the identification of ITGCN (11). Because of possible complications, application of this procedure is not recommended for all patients with unilateral disease (12). However, early diagnosis of contralateral ITGCN has clinical relevance. This is illustrated by the fact that the lifetime risk for TGCT is similar to the incidence of ITGCN in the general population, *i.e.*, no spontaneous regression of ITGCN occurs (13). Moreover, 50% of patients with ITGCN in the contralateral testis will develop an invasive TGCT within 5 years after diagnosis of ITGCN (14). Development of a second invasive TGCT will, in the majority of patients, require complete castration, resulting in need for hormone supplementation and psychological burden. ITGCN can be cured by low-dose irradiation, thereby preventing the development of an invasive tumor with preservation of the hormonal function in most patients (15, for review).

In view of this, there is clinical need for a predictive noninvasive test to identify TGCT patients at risk for bilateral disease. Here we report the novel finding that the presence of an activating codon 816 c-KIT mutation in a TGCT is associated with development of a contralateral TGCT. An activating c-KIT codon 816 mutation, encoding an Asp816His, has been reported previously in a single TGCT (16).

MATERIALS AND METHODS

Sample Handling and Characterization. The fresh tumors were collected in the southwestern part of the Netherlands. Representative parts of the tumors and adjacent testicular parenchyma were snap frozen or fixed overnight in 4% formalin for paraffin embedding. Diagnosis was made according to the recommendations of the WHO (1). This was confirmed by immunohistochemistry for the presence of OCT3/4, as described previously (8).

Additionally, two independent series were included, one collected in Hungary, consisting of DNA from 18 tumors (all second tumors), and a series of 6 unilateral TGCT with matched contralateral ITGCN-containing biopsies, collected in Norway.

From multiple 3- to 5- μ m-thick paraffin sections, tumor and ITGCN cells were dissected after deparaffinization with a sterile scalpel blade under direct microscopic visualization. Multiple 20- μ m-thick tissue sections from frozen samples were used. The cells were microdissected with the Arcturus Pixcell II system, after which DNA was isolated (digestion with 1 mg/ml proteinase K).

REMS AatII PCR. A modified 3' primer (exon 17R) was used to generate an AatII recognition site encompassing codon 816 (see Fig. 1). The presence of a mutation at this codon will result in disruption of the recognition site for the restriction endonuclease, leading to nondigested amplification products. Amplification was performed by PCR analysis using primers exon 17F (5'-TGTATTACAGAGACTTGGCA-3') and exon 17R (5'-TAATTAGAAT-CATTCTTGACG-3'), which yielded a 106-bp product. Reactions were carried out in a volume of 30 μ l containing 2.3 mM MgCl₂, 10 mM Tris-HCl (pH 8.3), 50 mM KCl, 1 μ M deoxynucleotide triphosphates, 0.33 μ M each primer, and 1.0 unit of *Taq* DNA polymerase (Qiagen). For each reaction, 50 ng of input DNA was used. PCR amplification was performed on a MJ Research Ther-

Received 6/27/03; revised 8/19/03; accepted 8/26/03.

Grant support: Supported financially by VanderEs Foundation and the Dutch Cancer Society (Koningin Wilhelmina Fonds/KWF), and in part by Hungarian Research Grants OM Szechenyi NKFP1/48/2001 and TKA-T030039.

The costs of publication of this article were defrayed in part by the payment of page charges. This article must therefore be hereby marked *advertisement* in accordance with 18 U.S.C. Section 1734 solely to indicate this fact.

Requests for reprints: Leendert H. J. Looijenga, Ph.D., Pathology/Laboratory for Experimental Patho-Oncology, Erasmus Medical Center/Daniel den Hoed Cancer Center, Josephine Nefkens Institute, Building Be, Room 430b, Dr. Molewaterplein 50, 3015 GE Rotterdam, the Netherlands. Phone: (31) 10 4088329; Fax: (31) 10 4088365; E-mail: L.Looijenga@erasmusmc.nl.

⁷The abbreviations use are: TGCT, testicular germ-cell tumor; ITGCN, intratubular germ cell neoplasia; PGC, primordial germ cell; REMS, restriction endonuclease-mediated selective; SNUPE, single-nucleotide primer extension.

mocycler with the following conditions: 95°C for 5 min of initial heat denaturation and 35 cycles of 95°C for 30 s, 45°C for 30 s, and 72°C for 30 s. Amplification products (10 μ l) were digested to completion with 5 units of *Aat*II (Fermentas) at 37°C overnight, yielding 85- and 21-bp fragments for wild-type amplification products. In contrast, in the presence of a mutation, no cleavage occurred.

The amplification products were cloned into a pCR TOPO-II vector and transformed in TOPO 10 One-Shot cells by use of the TOPO TA cloning kit (Invitrogen, Breda, The Netherlands). Inserts were sequenced (at least 10) on a Licor automated sequencer using a M13 Reverse primer.

SNuPE. Amplification was performed with primer set exon 17F (5'-TG-TATTACAGAGACTTGGCA-3') and exon 17R6 (5'-GTTTCCTTTAAC-CACATAATTAG-3') and yielded products 122 bp in length (for conditions, see above, with an annealing temperature of 56.5°C; see Fig. 2, left panel). Amplified fragments were purified by electrophoresis on a non-denaturing 10% polyacrylamide gel containing ethidium bromide, after which the fragments were dissected and eluted with elution buffer (containing 0.5 M ammonium acetate, 1 mM EDTA) at 37°C overnight. The SNuPE reaction (total volume, 10 μ l) contained 1.0 μ l of extracted PCR product, 1 pmol of reverse Y/Hr (5'-ATAATTAGAATCATTCTTGATGT-3') SNuPE primer for D816Y and H, and, for D816V, reverse primer D816Vr (5'-CATAATTAGAATCATTCT-TGATGT-3'); 10 mM Tris-HCl (pH 8.3); 50 mM KCl; 1.5 mM MgCl₂; 0.75 units of *Taq* DNA polymerase (Qiagen); and 0.2 μ l of [α -³²P]dATP or dGTP (3000 Ci/mmol; Amersham). Conditions for extension were 1 cycle of 95°C for 1 min, 58°C for 30 s, and 72°C for 30 s. The samples were analyzed by electrophoresis on a 15% denaturing polyacrylamide gel and subsequent autoradiography. As controls, cloned fragments of both proven mutated and wild-type sequences were used.

RESULTS

To screen for codon 816 mutations, we applied a REMS PCR approach to 110 primary consecutively collected TGCTs, including

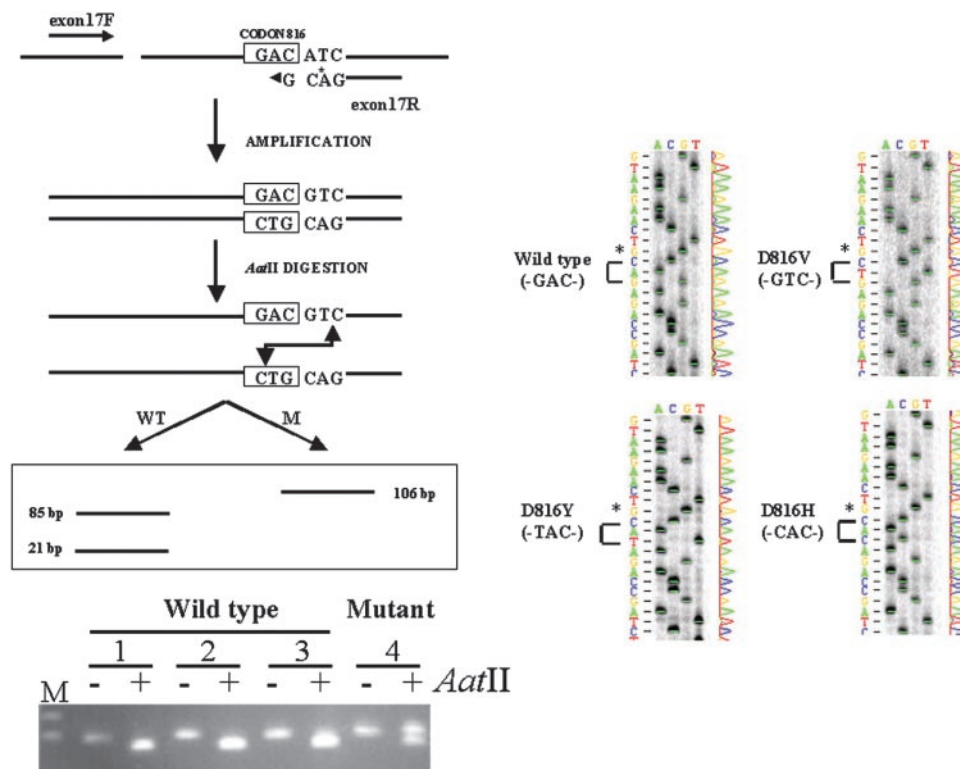


Fig. 1. Left, schematic representation of the REMS-PCR method to amplify both wild-type (WT) and codon 816-mutated (M) *c-KIT* alleles. Exon 17F and 17R primers are used, in which a mismatch nucleotide (C instead of T; indicated by *) is included at position 1 of codon 817. The amplification products (106 bp in length) derived from wild-type alleles are digested to completeness by the restriction endonuclease *Aat*II (leading to fragments of 85 and 21 bp), whereas the amplification products containing a genetic change at codon 816 are not digested. The restriction endonuclease recognition site is indicated by a double arrow. Representative examples of the size-separated amplification products by gel electrophoresis before and after *Aat*II digestion are shown. Note the presence of the digested 85-bp product in the wild-type samples (Lanes 1–3) and both the digested and undigested products (106 bp) in the mutant (Lane 4). Lane M, marker. Right, examples of the automated sequence analyses of cloned amplification products of the REMS PCR. Wild-type (GAG) and mutated alleles (GTC, valine; GAC, tyrosine; CAC, histidine) are shown. Note the G at position 1 of codon 817, introduced by the modified primer (exon17R), indicated by *.

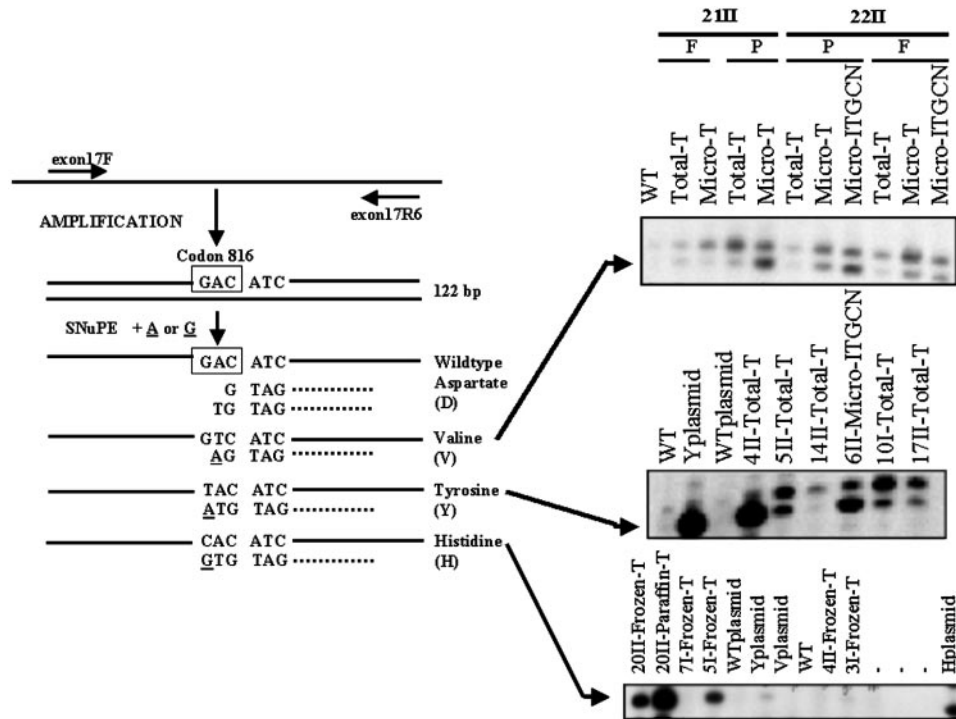


Fig. 2. *Left*, schematic representation of the SNUPE method for detecting mutated codon 816 *c-KIT* alleles. The presence of a GTC (encoding a valine; V), a GAC (encoding a tyrosine; Y), or a CAC (encoding a histidine; H) instead of a GAC (encoding an aspartate; wild type; WT) is specifically detected. The SNUPE primers are indicated as *dotted lines*. A radioactively labeled A nucleotide (*underlined*) is incorporated at position 2 of codon 816 in case of a GTC sequence and at position 1 in case of a GAC sequence, whereas a radioactively labeled G is incorporated at position 1 in case of a CAC sequence. None of these primers will lead to extension of an A or G nucleotide if only wild-type amplification products are present. *Right*, examples of detected mutations (V, Y, and H, indicated by an *arrow*) are shown. Both wild-type (WT) and mutated samples are indicated. Samples, both tumor (T) and precursor cells (ITGCN), are investigated without (Total) and after microdissection (Micro). In addition, cloned amplification products (plasmid) of wild-type or mutated alleles (Yplasmid, tyrosine; Vplasmid, valine; Hplasmid, histidine), as well as H₂O (–) are included as controls. The codes for the samples correspond to the codes used in Table 1. For some samples, the results obtained from DNA isolated from frozen (F) and paraffin-embedded (P) tissue are shown.

them contained the mutation (see Table 1). In addition, no mutation was found in the normal testicular parenchyma lacking ITGCN in the patients with bilateral disease. In 13 invasive TGCTs and in all ITGCN samples, the mutation was found only after microdissection (Table 1).

To confirm the association between *c-KIT* codon 816 mutations and bilateral TGCT, we investigated an independent series of 18 TGCT of patients with bilateral disease, for whom only DNA from the second tumor was available (see Table 2, *top*). Sixteen of the samples contained a mutation in codon 816 (89%). In addition, an independent series of six unilateral invasive TGCTs and matched ITGCNs of the contralateral testis (obtained by biopsy) were studied (see Table 2, *bottom*). Of one unilateral invasive tumor, only the ITGCN cells were available. No invasive TGCT was present in any of the biopsied testes. All primary TGCTs as well as the matched ITGCN of the same testis showed a mutation. All contralateral ITGCNs showed at least the same genetic change as the primary invasive tumor and matched ITGCN. Multiple mutations were found in four ITGCN samples, whereas a single mutation was detected in two.

DISCUSSION

Our data convincingly show that mutations affecting codon 816 of *c-KIT* are associated with development of bilateral TGCT. This was proven by investigation of three independently collected series of bilateral TGCTs. Although only a minority of unilateral TGCTs contained a codon 816 mutation (1.3%), it was present in the majority of the series of bilateral TGCTs (95, 89, and 100%, respectively; $P < 0.0001$, Fisher's exact test). This finding is of relevance to understand the biology of TGCT, because the *c-KIT*/stem cell factor

system is crucial for the proper migration and survival of PGCs (see Ref. 17 for a review). The stem cell factor is also one of the crucial components for *in vitro* survival of mouse and human PGCs (17), as well as human seminoma cells (18). *c-KIT* is a tyrosine kinase receptor of the subclass III family, for which the stem cell factor is the receptor. Binding of the ligand to the receptor results in receptor homodimerization and subsequent tyrosine kinase activity, leading to phosphorylation of various substrates. Downstream signaling pathways include proteins involved in regulation of apoptosis and cell proliferation (see Ref. 19 for a review). The codon 816 mutations result in a constitutively kinase-activated protein and phosphorylation of tyrosine residues, although with a change in the catalytic activity and substrate specificity compared with the wild-type receptor. No differences have been identified to date between the various types of codon 816 mutations regarding their biochemical properties.

This study shows that the *c-KIT* mutation in TGCTs is somatic in origin, in accordance to the findings of the International Testicular Cancer Linkage Consortium.⁸ Because of the presence of similar changes in the matched bilateral TGCTs, the findings support the model that bilateral TGCTs are monoclonal in origin. Although clinically unlikely (9, 10), the second TGCT might be a metastasis of the primary tumor to the contralateral testis. This possibility was excluded in our study by our investigation of six cases of unilateral invasive TGCT with matched contralateral ITGCN (without invasive disease), the latter identified by surgical biopsy. These findings favor the model

⁸ E. A. Rapley, S. Hockley, W. Warren, L. Johnson, R. Huddart, G. Crockford, *et al.* Somatic mutations of KIT in familial testicular germ cell tumours, submitted for publication.

Table 1 Summary of the clinical data and mutation analysis of *c-KIT* codon 816 in bilateral TGCTs

The mean age of the patients at time of clinical diagnosis of the first tumor was 31.9 years (range, 15–56 years); the mean age at diagnosis was 36.6 years for seminomas and 23.8 years for nonseminomas. The mean age at diagnosis of the second tumor was 38.3 years (range, 23–59 years; mean age, 40.3 years for seminomas and 28.5 years for nonseminomas). The mean difference in age between clinical presentation of the first and second (asynchronous) tumors was 7.0 years (range, 1–19 years). These figures are in accordance with published data (see Ref. 9 for a review).

Case	Tumor ^a	Age (years)	Histology ^b	Mutation ^c	ITGCN	Semen	PBL ^d	Remarks
1	I	51	SE	D816Y				
	II	56	SE	D816Y	D816Y ^e			
2	I	32	SE	D816Y	D816Y ^e			
	II	35	SE	D816Y		D816Y		
3	I	26	SE	D816V				During project ^f
	II	35	SE	D816Y+V ^e			WT	
4	I	24	NS	NA				
	II	37	SE	D816Y		D816Y		
5	I	28	NS	D816Y+H ^e				
	II	44	SE	D816Y				
6	I	33	SE	D816Y				
	II	37	SE	D816Y	D816Y ^e			
7	I	25	NS	D816Y		D816Y		
	II	35	NS	D816Y				
8	I	35	SE	NA				Familial ^g
	II	54	SE	D816Y+V+H ^e				
9	I	15	NS	D816Y+V+H ^e				
	II	24	NS	D816Y	D816Y ^e			
10	I	37	SE	D816Y				
	II	47	SE	D816Y+H				
11	I	41	SE	NA				
	II	51	SE	D816Y+V ^e				
12	I	35	SE	D816Y+V ^e			WT	
	II	35	SE	D816Y			WT	
13	I	28	NS	D816Y				
	II	30	SE	D816Y				
14	I	35	SE	D816Y+V ^e				
	II	44	SE	D816V				
15	I	22	NS	WT	D816Y+V+H ^e			
	II	23	NS	D816Y				
16	I	31	SE	D816Y+V+H ^e				
	II	34	SE	D816V	D816Y+V ^e			
17	I	56	SE	NA				
	II	59	SE	D816Y				
18	I	29	SE	NA				
	II	32	NS	D816Y+V ^e				
19	I	19	NS	NA				
	II	25	SE	WT	D816Y+V ^e			
20	I	36	SE	D816Y+V+H ^e	D816Y+V ^e			
	II	36	SE	D817H				
21	I	29	NS	NA				
	II	33	SE	D816Y+V ^e				
22	I	35	SE	D816Y+V ^e	D816Y+V ^e			
	II	36	SE	D816Y+V ^e	D816Y+V ^e			

^a I, first tumor; II, second tumor.

^b SE, seminoma; NS, nonseminoma. Tumors containing both seminomatous and nonseminomatous components (cases 4 I, 5 II, 6 I, 15 II, and 21 I) were classified as nonseminomatous.

^c Y, tyrosine (TAC); V, valine (GTC); H, histidine (CAC); NA, not available; WT, wild type (aspartate, D; GAC).

^d PBL, peripheral blood.

^e Mutation was detected only after microdissection.

^f Became bilateral during the course of the project.

^g Familial disposition.

that the mutation occurs during or before migration of PGCs to the genital ridge.

Of the 224 unilateral TGCTs, 4 (1.8%) showed a mutation. One of these patients developed a bilateral TGCT (Table 1, case 3) during the period of this project. The second TGCT in this patient was diagnosed 9 years after the first. To date, none of the other three patients developed a second tumor. No contralateral biopsy was done. The ages of these patients at initial diagnosis were 26, 34, and 41 years, being 10, 7, and 7 years ago, respectively. As indicated based on the data presented in Table 1, the time between diagnosis of the first and second TGCT in a single patient is, on average, 7.0 years but can be up to 20 years, in accordance with published data (9, 20). Because of the knowledge that no spontaneous regression of ITGCN occurs (13), these patients will be kept under close examination.

At least two of the patients with a bilateral TGCT from our investigated series (Table 1, case 8; Table 2, top, case 1) had an affected brother (for which the tumors were not available for analy-

ses). This indicates that the presence of a *c-KIT* mutation is not restricted to sporadic TGCT, which was confirmed in the study of the International Testicular Cancer Linkage Consortium.⁸ That study showed no germline mutations in 240 pedigrees of families with at least two patients with TGCT. In addition, a significantly higher number of *c-KIT* mutations were found in bilateral *versus* unilateral TGCT. The finding that not all bilateral TGCTs in the familial context contained a mutation might be because of the familial predisposition. Familial predisposition might be an alternative mechanism to a *c-KIT* mutation for promotion of bilateral disease. Alternatively, it might be attributable to the fact that no ITGCN was investigated. We showed that although the invasive TGCT could lack a mutated *c-KIT*, the mutation is present in the precursor lesion. Further investigation could shed light on the possible role of common intrauterine etiological factors in the development of TGCT (21).

We demonstrated that a mutation of codon 816 in *c-KIT* is associated with development of bilateral TGCT. These kinds of mutations

Table 2 Summary of *c-KIT* codon 816 mutation analysis in two independent series of proven bilateral TGCTs

For the results in the top portion, only the second tumor was investigated (collected in Hungary). In the bottom portion, the primary tumor with adjacent ITGCN, as well as contralateral ITGCN, were identified based on biopsy analysis (collected in Norway) see Table 1 for further explanations.

Case	Age (years)	Histology	Mutation
1 ^a	24	SE ^b	D816V
2	41	NS	D816Y+V
3	42	SE	D816Y+V
4	35	SE	D816V
5	25	SE	D816V
6	22	NS	WT
7	40	SE	D816Y+V
8	26	SE	D816Y+V
9	36	NS	D816Y+V
10	20	NS	D816V
11	28	NS	D816V
12	52	SE	D816V
13	33	SE	D816Y
14	41	SE	D816V
15	45	SE	WT
16	35	SE	D816Y+V
17	23	NS	D816Y
18	47	SE	D816V

Contralateral biopsy with ITGCN			
1		ITGCN	D816V
		SE	D816Y+V+H
2		SE	D816Y+V
3		ITGCN	D816Y+V
4		ITGCN	D816Y+V+H
		SE	D816Y+V
5		SE	D816Y+V
6		SE	D816V

^a Familial.

^b SE, seminoma; NS, nonseminoma.

have been found previously in a single TGCT and an ovarian germ cell tumor (16). In addition, they have been identified in human mastocytosis, acute myeloid leukemia, and sinonasal natural killer/T-cell lymphoma (see Ref. 19 for a review). The activating mutations, as reported in gastrointestinal stromal tumors, do not affect exon 17 but do affect exons 9 or 11. These mutations result in ligand-independent receptor dimerization, leading to kinase activity on the receptor. This is in contrast to the intrinsic kinase activity in the case of codon 816 mutations. The tyrosine kinase inhibitor STI571 (imatinib mesylate; Gleevec) has been found to be effective for treating gastrointestinal stromal tumors. In contrast, this small molecule does not inhibit *c-KIT* containing codon 816 mutations (see Ref. 19 for a review), as found in TGCT (Ref. 16 and this study).

The activating mutations detected in TGCT likely occur during early embryonal development. Therefore, *c-KIT* codon 816 mutations are highly penetrant genetic changes for embryonic germ cells, leading to development of bilateral TGCT. The presence of such a mutation in a TGCT indicates a high risk for bilateral disease. Because of the occasional absence of the mutated allele in the invasive tumor, analysis of both the invasive tumor and the ITGCN is recommended. This finding could modify present management and counseling of patients with a unilateral TGCT, making open surgical biopsy for identification of contralateral ITGCN superfluous in the majority of patients with a unilateral TGCT. It could facilitate improved treatment of patients prone to develop bilateral disease, either by a watch-and-wait strategy or by use of localized low-dose gonadal irradiation, which should not affect hormonal function in the majority of patients (15). It remains to be investigated whether specific tyrosine kinase

inhibitors, such PPI and PP2 (22), might be effective in chemoprevention of progression of contralateral ITGCN to an invasive TGCT in patients with a clinically proven unilateral TGCT with a *c-KIT* codon 816 mutation.

ACKNOWLEDGMENTS

We thank Elizabeth Rapley and Mike Stratton (Institute of Cancer Research, Section of Cancer Genetics, Sutton, Surrey, United Kingdom) for critical reading of the manuscript.

REFERENCES

- Mostofi, F. K., and Sesterhenn, I. A. Histological typing of testis tumours, Ed. 2, p. 132. Berlin: Springer, 1998.
- Adami, H. O., Bergström, R., Möhner, M., Zatonski, W., Storm, H., Ekblom, A., Trethi, S., Teppo, L., Ziegler, H., Rahu, M., Gurevicius, R., and Stengrevics, A. Testicular cancer in nine northern European countries. *Int. J. Cancer*, 59: 33–38, 1994.
- Skakkebaek, N. E., Holm, M., Hoei-Hansen, C., Jørgensen, N., and Rajpert-De Meyts, E. Association between testicular dysgenesis syndrome (TDS) and testicular neoplasia: evidence from 20 adult patients with signs of maldevelopment of the testis. *Apmsis*, 111: 1–11, 2003.
- Skakkebaek, N. E. Possible carcinoma-in-situ of the testis. *Lancet*, 2: 516–517, 1972.
- Møller, H. Decreased testicular cancer risk in men born in wartime. *J. Natl. Cancer Inst. (Bethesda)*, 81: 1668–1669, 1989.
- Jørgensen, N., Giwercman, A., Müller, J., and Skakkebaek, N. E. Immunohistochemical markers of carcinoma in situ of the testis also expressed in normal infantile germ cells. *Histopathology*, 22: 373–378, 1993.
- Rajpert-De Meyts, E., and Skakkebaek, N. E. Expression of the *c-kit* protein product in carcinoma-in-situ and invasive testicular germ cell tumours. *Int. J. Androl.*, 17: 85–92, 1994.
- Looijenga, L. H. J., Stoop, H., De Leeuw, P. J. C., De Gouveia Brazao, C. A., Gillis, A. J. M., Van Roozendaal, K. E. P., Van Zoelen, E. J. J., Weber, R. F. A., Wolffbuttel, K. P., Van Dekken, H., Honecker, F., Bokemeyer, C., Perlman, E. J., Schneider, D. T., Kononen, J., Sauter, G., and Oosterhuis, J. W. POU5F1 (OCT3/4) identifies cells with pluripotent potential in human germ cell tumors. *Cancer Res.*, 63: 2244–2250, 2003.
- Holzbeierlein, J. M., Sogani, P. C., and Sheinfeld, J. Histology and clinical outcomes in patients with bilateral testicular germ cell tumors: the Memorial Sloan Kettering cancer center experience 1950 to 2001. *J. Urol.*, 169: 2122–2125, 2003.
- Lajos, G., Gomez, F., Mihaly, B., and Istvan, B. The incidence, prognosis, clinical and histological characteristics, treatment and outcome of patients with bilateral germ cell testicular cancer in Hungary. *J. Cancer Res. Clin. Oncol.*, in press, 2003.
- Dieckmann, K. P., and Loy, V. Prevalence of contralateral testicular intraepithelial neoplasia in patients with testicular germ cell neoplasms. *J. Clin. Oncol.*, 14: 3126–3132, 1996.
- Heidenreich, A., and Moul, J. W. Contralateral testicular biopsy procedure in patients with unilateral testis cancer: is it indicated?. *Semin. Urol. Oncol.*, 20: 234–238, 2002.
- Giwercman, A., Müller, J., and Skakkebaek, N. E. Prevalence of carcinoma-in-situ and other histopathological abnormalities in testes from 399 men who died suddenly and unexpectedly. *J. Urol.*, 145: 77–80, 1991.
- Berthelsen, J. G., Skakkebaek, N. E., von der Maase, H., Sorensen, B. L., and Mogensen, P. Screening for carcinoma in situ of the contralateral testis in patients with germinal testicular cancer. *Br. Med. J. (Clin. Res. Ed.)*, 285: 1683–1686, 1982.
- Rorth, M., Rajpert-De Meyts, E., Andersson, L., Dieckmann, K. P., Fossa, S. D., Grigor, K. M., Hendry, W. F., Herr, H. W., Looijenga, L. H. J., Oosterhuis, J. W., et al. Carcinoma in situ of the testis. *Scand. J. Urol.*, 205: 166–186, 2000.
- Tian, Q., Frierson, H. F., Jr., Krystal, G. W., and Moskaluk, C. A. Activating *c-kit* gene mutations in human germ cell tumors. *Am. J. Pathol.*, 154: 1643–1647, 1999.
- Shablott, M. J., Axelman, J., Wang, S., Bugg, E. M., Littlefield, J. W., Donovan, P. J., Blumenthal, P. D., Huggins, G. R., and Gearhart, J. D. Derivation of pluripotent stem cells from cultured human primordial germ cells. *Proc. Natl. Acad. Sci. USA*, 95: 13726–13731, 1998.
- Olie, R. A., Boersman, A. W. M., Dekker, M. C., Nooter, K., Looijenga, L. H. J., and Oosterhuis, J. W. Apoptosis of human seminoma cells upon disruption of their micro-environment. *Br. J. Cancer*, 73: 1031–1036, 1996.
- Heinrich, M. C., Blanke, C. D., Druker, B. J., and Corless, C. L. Inhibition of KIT tyrosine kinase activity: a novel molecular approach to the treatment of KIT-positive malignancies. *J. Clin. Oncol.*, 20: 1692–1703, 2002.
- Colls, B. M., Harvey, V. J., Skelton, L., Thompson, P. I., and Frampton, C. M. Bilateral germ cell testicular tumors in New Zealand: experience in Auckland and Christchurch 1978–1994. *J. Clin. Oncol.*, 14: 2061–2065, 1996.
- Akre, O., Ekblom, A., Hsieh, C. C., Trichopoulos, D., and Adami, H. O. Testicular nonseminoma and seminoma in relation to perinatal characteristics. *J. Natl. Cancer Inst. (Bethesda)*, 88: 883–889, 1996.
- Tatton, L., Morley, G. M., Chopra, R., and Khwaja, A. The Src-selective kinase inhibitor PPI also inhibits Kit and Bcr-Abl tyrosine kinases. *J. Biol. Chem.*, 278: 4847–4853, 2003.

Cancer Research

The Journal of Cancer Research (1916–1930) | The American Journal of Cancer (1931–1940)

Stem Cell Factor Receptor (c-*KIT*) Codon 816 Mutations Predict Development of Bilateral Testicular Germ-Cell Tumors

Leendert H. J. Looijenga, Hubert de Leeuw, Monique van Oorschot, et al.

Cancer Res 2003;63:7674-7678.

Updated version Access the most recent version of this article at:
<http://cancerres.aacrjournals.org/content/63/22/7674>

Cited articles This article cites 18 articles, 6 of which you can access for free at:
<http://cancerres.aacrjournals.org/content/63/22/7674.full#ref-list-1>

Citing articles This article has been cited by 12 HighWire-hosted articles. Access the articles at:
<http://cancerres.aacrjournals.org/content/63/22/7674.full#related-urls>

E-mail alerts [Sign up to receive free email-alerts](#) related to this article or journal.

Reprints and Subscriptions To order reprints of this article or to subscribe to the journal, contact the AACR Publications Department at pubs@aacr.org.

Permissions To request permission to re-use all or part of this article, use this link
<http://cancerres.aacrjournals.org/content/63/22/7674>.
Click on "Request Permissions" which will take you to the Copyright Clearance Center's (CCC) Rightslink site.